

Comparative Analysis of Palatine Rugae in Children Aged 5 to 8 Years: Comparative Analysis by Sex

Thalia Gabriela Alvarez Centeno¹, Carlos Gustavo Martínez Florencia¹

Available online at: www.xournals.com

Received 20th January 2025 | Revised 18th February 2025 | Accepted 25th February 2025

Abstract:

This study focuses on the comparative analysis of palatal rugae in boys and girls aged 5 to 8, aiming to identify morphological patterns that may aid in forensic identification. Palatal rugoscopy, an increasingly important tool in forensic dentistry, examines palatal rugae—anatomical structures that, due to their stability and uniqueness, can be critical in individual identification. Despite previous studies in adults, pediatric populations have been less explored, highlighting the need for research in this age group. The study was conducted with a sample of 25 children from the Pediatric Dentistry Clinic of the University of Guayaquil, selected based on specific criteria and with parental consent. Extra-hard plaster models were used to capture the rugae, applying Basauri Chávez's classification to categorize each ruga type by form and position, with numerical values assigned to facilitate comparative analysis by gender. Results revealed differences in straight and sinuous rugae, more frequent in girls, while "point" and "curve" rugae were predominant in boys. Independent observers following a blind method increased the reliability of the data. These patterns suggest a possible relationship between gender and rugae morphology, supporting palatal rugoscopy's utility as a forensic tool in children. This research provides significant evidence for using rugoscopy in pediatric forensic dentistry and promotes further studies that consider variables like ethnic origin and environmental factors to enhance identification accuracy.

Keywords: Dentistry - Forensic - Rugoscopy - Palatine Rugae - Anatomy

Authors:

1. Dentist, Master in Forensic Medicine, University of Guayaquil, Ecuador.

Introduction

Palatal rugoscopy, or the study of palatal rugae, is a widely used tool in forensic dentistry for individual identification due to the uniqueness and stability of these structures over time (Patil *et al.*, 2008). Palatal rugae are connective tissue folds located on the palate mucosa and exhibit morphological patterns that remain relatively stable from early life, allowing for their analysis in both pediatric and adult populations (Nayak *et al.*, 2014). These structures, which vary in number, length, and shape, develop in the first weeks of life and resist changes induced by external factors, such as mechanical wear, age, or diseases (Venegas *et al.*, 2009). Therefore, they have become a valuable resource in forensic identification and anthropological studies.

Previous studies have shown variations in palatal rugae patterns among individuals of different genders and age groups. According to (Fonseca and Flórez, 2009), these structures have a specific arrangement and morphology that may be influenced by genetic and environmental factors. The classification of palatal rugae into types such as straight, sinuous, curved, and angular facilitates a systematic analysis, enabling comparison across different population groups (Patil *et al.*, 2008). In this context, Basauri Chávez developed a classification system that assigns numerical values to different rugae types, allowing for more precise identification and reducing subjective bias during registration (Fonseca and Flórez, 2009).

Research on palatal rugae in pediatric populations is particularly relevant since these structures develop early and retain their morphology throughout life, allowing for study from a young age. In children, it has been observed that palatal rugae can differ by gender, showing patterns that, while not entirely exclusive, present tendencies useful for forensic identification (Santos *et al.*, 2016). This is especially important in the pediatric population, where traditional identification methods such as fingerprints or DNA may be less accessible or applicable in certain contexts (Caldas *et al.*, 2007). The objective of this study is to analyze palatal rugae in a sample of children aged 5 to 8, segmented by gender, to determine if there are distinctive patterns that may facilitate forensic identification of individuals in the pediatric population. This approach responds to the need for studies addressing the characteristics of palatal rugae in pediatric populations, as most previous studies have focused on adults (Nayak *et al.*, 2014). This study focuses on the upper arch and uses a rugoscopic record based on Basauri Chávez's classification, which enables a detailed and precise description of the rugae, classifying them as straight, curved, angular, sinuous,

among others, and assigning numerical values to each type for easier statistical analysis (Fonseca and Flórez, 2009).

Forensically, identifying palatal rugae patterns in children can be useful in scenarios where identifying minors is complex due to the absence of prior records or in situations where other identification methods are not applicable. According to (Caldas *et al.*, 2007), rugoscopy is a non-invasive, low-cost, and quick method, making it a viable alternative for identification in forensic contexts, especially for children. By exploring gender differences in the morphology of palatal rugae, this study contributes to understanding anatomical variability in childhood, which is crucial for advancing the development of accurate identification methods tailored to specific populations. This research aims to provide evidence on the variations of palatal rugae based on gender in a pediatric population, thereby strengthening the use of palatal rugoscopy as a tool in forensic dentistry. Based on these findings, it is expected to contribute to forensic knowledge and facilitate future research exploring other factors that may influence palatal rugae morphology, such as ethnic origin and environmental influences (Venegas *et al.*, 2009; Santos *et al.*, 2016).

Objectives

The objective of this study is to analyze and compare the morphological characteristics of palatine rugae in boys and girls aged 5 to 8 years, to identify distinctive patterns of frequency and shape according to gender. Through a detailed classification of the rugae on both sides of the upper arch, this study aims to contribute to forensic dentistry by providing information that may facilitate the identification of gender profiles in the pediatric population through the analysis of palatine rugae.

Methods and methodology adopted.

The research design is observational, descriptive, and comparative. This approach allows for the observation and documentation of characteristics of palatine rugae based on variables such as sex and age. A quantitative approach would be chosen, as it facilitates the numerical coding of the characteristics of palatine rugae, such as their shape, position, and quantity. This classification provides a solid foundation for statistical analysis, which is necessary to identify patterns in the sample.

The sample selection consisted of pediatric patients at the Pediatric Dentistry Clinic of the Faculty of

Dentistry at the University of Guayaquil, including both boys and girls aged between 5 and 8 years, excluding those with a history of dental treatments that may have altered the palatine structure, or with congenital conditions affecting the morphology of the palate. The main variables are the type of palatine ruga, its position relative to the midline (right or left), and the number of rugas. Additionally, variables such as sex and age will be controlled to make significant comparisons between the groups.

Data collection begins with obtaining palatine impressions from each participant, using materials such as dental alginate, which captures precise details of the palate. These impressions will be used to create extra-hard plaster models, allowing for the observation and analysis of the rugae without the need to continuously involve the participants. For detailed recording, a special rugoscopic form created by the authors will be used to document the characteristics of each ruga according to the Basauri Chávez classification, including the type, shape, and position of the midline raphe. The form will also contain basic identification data, such as the participant's name, age, sex, and identification number, facilitating a clear organization of the sample.

FICHA RUGOSCÓPICA

Datos de Filiación

Número de Paciente: _____

Nombre: _____

Sexo: Femenino _____ Masculino _____ Edad: _____

Ficha Rugoscópica: Anotar los números del 0 al 9 de acuerdo al número de ruga palatina correspondiente, empezando desde el centro de la tabla hacia el exterior (Centro a Derecha – Centro a Izquierda).

| DERECHA | | IZQUIERDA | |
|---------|--|-----------|---|
| 0 | | | 0 |
| 1 | | | 1 |
| 2 | | | 2 |
| 3 | | | 3 |
| 4 | | | 4 |
| 5 | | | 5 |
| 6 | | | 6 |
| 7 | | | 7 |
| 8 | | | 8 |
| 9 | | | 9 |

| Forma | Clasificación | Valor |
|-------------|---------------|-------|
| • Simple | Punto | 0 |
| ✓ Simple | Recta | 1 |
| ✓ Simple | Curva | 2 |
| ✓ Simple | Angulo | 3 |
| ✓ Simple | Sinuosa | 4 |
| ✓ Simple | Círculo | 5 |
| T Compuesta | Yé | 6 |
| W Compuesta | Cáliz | 7 |
| W Compuesta | Raqueta | 8 |
| W Compuesta | Rama | 9 |

Realizado por: _____

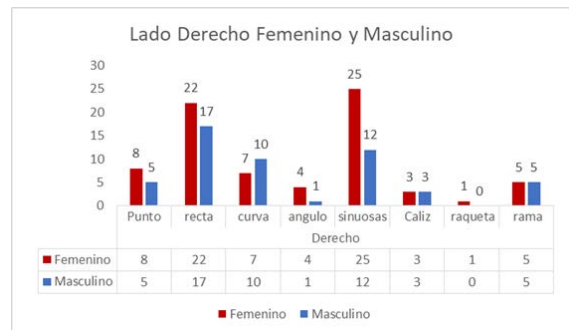
Figure No. 1: Custom Rugoscopic Sheet

To minimize potential biases, two independent observers participated, conducting the analysis and filling out the rugoscopic forms without knowing the participant's sex. This "blind" procedure helps avoid subjective and biased interpretations. Each observer independently recorded the characteristics of the wrinkles, and in case of discrepancies in classification, a second joint observation will be carried out to reach a consensus. This inter-observer control is evaluated through concordance indices, such as the Kappa coefficient, which ensures the reliability of the classification and reduces information bias.

Once collected, the data will be consolidated into a digital database to facilitate statistical analysis. The classification of palatine rugae will be coded according to the Basauri Chávez classification, which simplifies statistical comparison. Descriptive statistical tests (such as frequencies and distributions) will allow for the characterization of the morphology of the rugae based on the main variables. This will enable the establishment of whether there are significant differences in the morphology of the rugae between boys and girls of different ages. This methodology and the detailed methods ensure precise and reliable research, contributing to the understanding of the development of palatine rugae at an early age and their possible application in forensic dentistry.

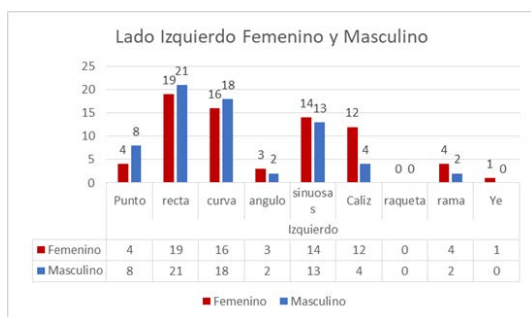
Discussion

The research was conducted on twenty-five pediatric patients at the Pediatric Dentistry Clinic of the Faculty of Dentistry at the University of Guayaquil, including both boys and girls aged between 5 and 8 years, excluding those with a history of dental treatments that may have altered the palatine structure, or with congenital conditions affecting the morphology of the palate, who participated with informed consent from their parents and met the inclusion criteria.



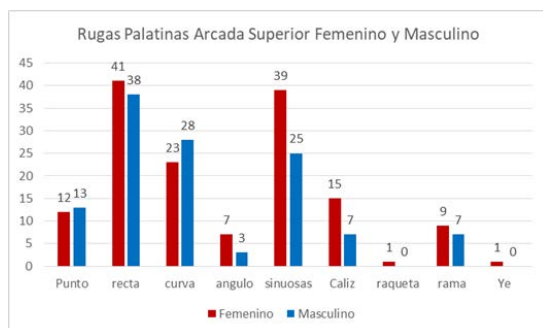
Graph No. 1: Comparison of the Right Side: Female and Male.

In the analysis of the palatine rugae on the right side, differences between genders are observed. The "straight" and "wavy" rugae stand out in girls with frequencies of 22 and 25, respectively, compared to 17 and 12 in boys, suggesting a possible preference for these types in the female group. The "curved" and "point" rugae also show higher frequencies in girls (10 and 8) compared to boys (7 and 5). However, for rugae such as "chalice," "racket," and "branch," the frequencies are similar between both genders, indicating stability in these types. These patterns may support forensic identification by gender.



Graph No. 2: Comparison of the Left Side: Female and Male.

The analysis of palatine ridges on the left side reveals differences and similarities between genders in the studied pediatric population. The ridges "straight" and "curved" show a high frequency in both groups, although boys have slightly higher frequencies (21 and 18, respectively) compared to girls (19 and 16). The "sinuous" ridges are also common, although in this case, girls have a higher frequency (14) than boys (13). On the other hand, the "point" type is more frequent in boys (8) than in girls (4), while "chalice" is more prevalent in girls (12). Other types, such as "racket," "branch," and "yé," show minimal or similar frequencies. This differential pattern may be relevant in forensic identification by gender.



Graph No. 3: Comparison of Superior Arch Rugae: Female and Male.

The analysis of palatine rugae in the upper arch shows variations between genders. The "straight" and "wavy" rugae are the most common in both sexes, although they are more prevalent in girls (41 and 39, respectively) compared to boys (38 and 25), suggesting a predisposition in the female group towards these types. The "curved" rugae are also more common in girls (28) than in boys (23). In contrast, the "point" type is slightly more frequent in boys (13) than in girls (12), while the "chalice" rugae are more prevalent in girls (15) than in boys (7). Other types, such as "racket," "branch," and "ye," have low or equivalent frequencies. These patterns may be useful

in the forensic field for establishing gender differences.

Conclusion

The analysis of palatal rugae in a sample of children aged 5 to 8 revealed differentiated morphological patterns between genders, which may be useful for forensic identification in pediatric populations. Straight and sinuous rugae predominated in the female gender, suggesting a predisposition among girls toward these specific types of rugae, while boys showed a higher frequency of "point" and "curve" types. These findings are consistent with previous studies that highlight the utility of palatal rugoscopy as a forensic tool due to the stability and uniqueness of palatal rugae over a lifetime (Patil *et al.*, 2008; Nayak *et al.*, 2014).

Studies such as those by (Venegas *et al.*, 2009) and (Santos *et al.*, 2016) have also noted variations in palatal rugae morphology based on gender and other factors like ethnic origin, suggesting that these patterns may be influenced by both genetic and environmental factors. In the context of forensic identification in children, where traditional methods such as fingerprints may be less applicable, palatal rugoscopy presents itself as a viable alternative, especially in cases where there are no prior records of the child's identity (Caldas *et al.*, 2007). The implementation of standard recording methods and rugae classification, such as Basauri Chávez's proposal, facilitates comparative analysis and reduces subjective bias, thereby allowing for greater precision in identification (Fonseca and Flórez, 2009).

The inclusion of independent observers in this study contributed to the reliability of the results, minimizing variability in rugae classification. Additionally, the use of statistical analysis in data interpretation provides a solid foundation for future research that explores the relationship between palatal rugae morphology and other demographic factors. This research provides valuable evidence on the morphology of palatal rugae based on gender in a pediatric population, highlighting the importance of palatal rugoscopy as a forensic tool in dentistry. The patterns observed in palatal rugae in girls and boys could contribute to the development of specific identification profiles for pediatric populations. Future research should consider other factors, such as ethnic origin and environmental influences, to broaden the understanding of palatal rugae morphology and enhance its application in forensic dentistry.



References:

Caldas, Inês Morais et al. "Establishing identity using cheiloscopy and palatoscopy." *Forensic science international*, vol. 165,1, 2007, pp. 1-9.

Fonseca, Gabriel Mario, and Carlos David Rodríguez Flórez. "Propuesta De Codificación Y Análisis De Rugosidades Palatinas Para Su Aplicación En Odontología Antropológica Y Forense." *Oral*, vol. 10, no. 31, Jan. 2009, pp. 518–23.

Nayak, P y et al. "Palatal rugae pattern in forensic identification." *Journal of Forensic Dental Sciences*, 2014, pp. 122 - 128.

Patil, M. S. y et al. "Rugoscopy: Current and future trends." *Journal of Forensic Dental Sciences*, 2008, pp. 45-51.

Santos, C: et al. "Rugas palatinas y género en población infantil: un estudio exploratorio." *Odontología Pediátrica*, 2016, pp. 301-308.

Venegas, Valeria Hermosilla, et al. "Palatal Rugae: Systematic Analysis of Its Shape and Dimensions for Use in Human Identification." *International Journal of Morphology*, vol. 27, no. 3, Sept. 2009.