

Sexual Dimorphism through Pelvic Bone

Gunjan Jindal¹

Available online at: www.xournals.com

Received 2nd September 2018 | Revised 15th October 2018 | Accepted 13th December 2018

Abstract:

The most important and reliable step in forensic anthropology is to identify the sex from skeletal remains of an unknown individual by forensic experts and archeologists. The sex determination in human skeleton using different methods such as visual examination, X-ray examination, microscopic examination, bones anthropometric measurements and anthropometric measurement with use of statistics. This paper is focus on sex determination using hip bone which is consider as an ideal bone and provides the highest accuracy levels. The hip bone contain the dissimilarities between the two sexes in which female hip bone adapt the capacity of childbearing. According to Krogman, the degree of accuracy in sex determination through bones is as pelvis gives the 95% accuracy alone. In pelvis, Sciatic Notch Index is considered as the best criteria for sex determination.

Keywords: Pelvic Bone, Sciatic Notch Index, Skeletal Remains

Authors:

1. Galgotias University, Greater Noida, Uttar Pradesh, INDIA

Introduction

Classification of an individual whether is male or female is called sex determination (**Black and Ferguson, 61**). Determination of sex considered as one of the easiest and straightforward biological characteristics from remain human skeleton. Sex determination are done by the various skeleton remain like mandible, pelvis, scapula, sacrum etc. (**Fairgrieve, 36**). All living human beings have discrete trait due to which they are determined by genetic makeup. They have all identifiable characteristics that is used for the purpose to classify any individual into two categories such as male and female. In human skeleton, it is much more difficult to determine the sex on the basis of shape and size traits but sexing methods are categorized into two parts, one is morphological (shape) and second is metric (size) (**Iscan, 143; Tarrant and Shirley, 139**). The key components for determine the skeleton sex are archaeological and medicolegal contexts. More morphological aspects to specifying the sex from human skeleton are found in pelvis bone, not in other bones of body and metric differences are found in human skeleton skull as well as in postcranial skeleton. Both categories have highest accuracy rate, in which pelvic bone contain the 95% accuracy alone but both have the 98% accuracy (**Tarrant and Shirley, 139**). The determination of sex of skeleton is the concern problem for paleodemographers, paleoanthropologists and forensic scientists (<http://medind.nic.in>).

In this paper, we will discussed about the sex determination from pelvis bone which have the highest accuracy rate. Innominate bones or ossa coxae (ilium, ischium and pubic) and a sacrum bone are formed the pelvis bone in adulthood. Through these bone, bowl-shaped is created and support the lower trunk's organ such as uterus, bladder, intestine and so forth. The bony structures are provided through the human pelvis and this structure makes the bipedal locomotion (upright walking) (**Burns, 109**). The bony structure is used to determine the sex of individual on basis of function of female pelvis which is different from the male pelvis (**Matshes, 327**). Female pelvis have selective pressure for childbirth but in case of too narrow pressure, her and her child's life are in risk (**Dirkmaat, 241**).

Pelvic Girdle

Determination of sex is done by pelvis which is most reliable area of the skeleton. Only one piece of bone of pelvis could be identified by the fragmented bone (**Brickley and Ferlini, 77**). Difference between male and female are done by the multiple morphological features.

- Two innominate bones with coccyx (tailbone) and sacrum are formed the pelvic girdle.
- The junction is seen between the lower limbs and trunk.
- Through oblique plane, it is divided into lesser (true) and greater (false) pelvis, and the circumference of pelvic girdle is called pelvic brim.
- The true pelvis is adjust below the pelvis brim and bounded with the coccyx and sacrum on the either side by fascia, bony pubic region, innominates, musculature and other soft tissues.
- The false pelvis is adjust above the oblique plane and bounded on either side by muscular abdominal wall and blades of the ilium.
- Both pelvic inlet and pelvic outlet are contained by lesser (true) pelvis in which pelvic inlet present at superior position while the pelvic outlet present at inferior position (**Matshes, 328**).

Innominate Bone

- These type of bone are irregular, large and blade-shape.
- Three separated bones are formed the innominate bone and these are ilium, ischium and pubis.
- The ilium bone of innominate is large and wing like region.
- The ischium contain the C-like shaped of dense bone.
- The pubis bone of innominate is flat like bone.

- In humans, the innominate bones is most sexually dimorphic bone.
- The bones of innominate are articulate with the opposing innominate (symphysis of pubic), with the femur (acetabulum) and with the sacrum (sacroiliac joint).

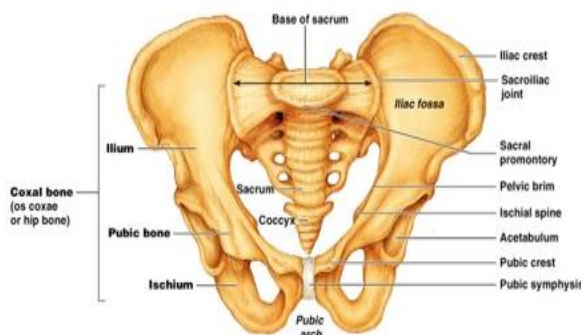


Figure – Pelvic Bone

Difference between Male and Female from Temporal Development of Pelvis

At the time of development of fetal stage, sexual dimorphism starts as early as. After the 26-27th

gestation period, morphological differences (greater inter ischiatic distance) in fetal females could be the cause of pathological fetal development. When child grows into an adult then the differences between the male and female are increasingly pronounced and divergent. The sex difference in between acetabular and ischium are seen at the age of 8 years but most of the sexual dimorphism is seen during the adolescent growth. At the same time period, female shows significant greater growth in pelvic cavity while male in acetabulum (<https://www.ncbi.nlm.nih.gov>).

Sex Determination

In the sex determination, there are two methods of analysis, one is metric analysis and another one is non-metric analysis. Non-metric analysis contains the visual and qualitative assessment of skeletal features which vary between males and females. In given table, there are some features which vary between males and females (**Christensen, Passalacqua and Bartelink, 203**). So many differences occur between male and female pelvis and these differences are related to female for giving birth to child because baby is birth through the pelvis for which female's pelvis inlet and outlet are wide.

Table – Difference between Female and Male Pelvic Bone (Christensen, Passalacqua and Bartelink, 204; Adams, 47; Grant and Roberts, 73; Klepinger, 26; Fairgrieve, 21; Rathbun and Buikstra, 232; Iscan and Steyn, 147; Siegel, Saukko and Houck, 37; Klepinger, 46)

Pelvic Features	Female	Male
Architecture	Less massive, gracile, smoother	Massive, rugged, marked muscle site
Ilium	Wide, low and flared	Vertical and high
Pelvic Inlet or brim	Oval, elliptical and circular	Heart-Shaped
Ventral Arc	Present	Absent
Sub-Pubic Concavity	Present	Absent
Medial Ischiopubic ramus	Narrow and sharp	Wide and dull
Obturator foramen	Small and triangular	Large and ovoid

Sub-pubic Angle	Larger (obtuse, greater than 90 degree), U-shaped	Smaller (acute, less than 90 degree), V-shaped
Sub-pubic Shape	Concave	Convex
Acetabulum	Smaller, tends to be directed anterolaterally	Larger, tends to be directed laterally
Sacral Shape	Short, straight and wide	Long, curved and narrow
Greater Sciatic notch	Larger, wider, shallower	Smaller, close, deep
Preauricular Sulcus	Present, more frequent and better developed	Absent, not frequent
Postauricular Sulcus	More frequent, sharper, auricular surface edge	Not frequent
Pubis Ramus	1.5:1, Strongly everted	1:1, Slightly everted
Pubic Bone Shape	Rectangular	Triangular
Auricular Surface	Elevated	Flush with ilium
Postauricular Space	Wide	Narrow
Sacral Dimension	Alae wider than promontory	Alae narrower than promontory
Pubis symphysis	Lower	Higher
Sacroiliac joint	Small, oblique	Large
Iliac Tuberosity	Small or absent, pointed or varied	Large, not pointed
Sacrum	Shorter, broader, with tendency of marked curvature at S1-2 and S1-5; 5 segments the rule	Longer, narrower, with more evenly distributed curvature often 5 or more segments
True pelvis or cavity	Oblique, shallow, spacious	Relatively smaller

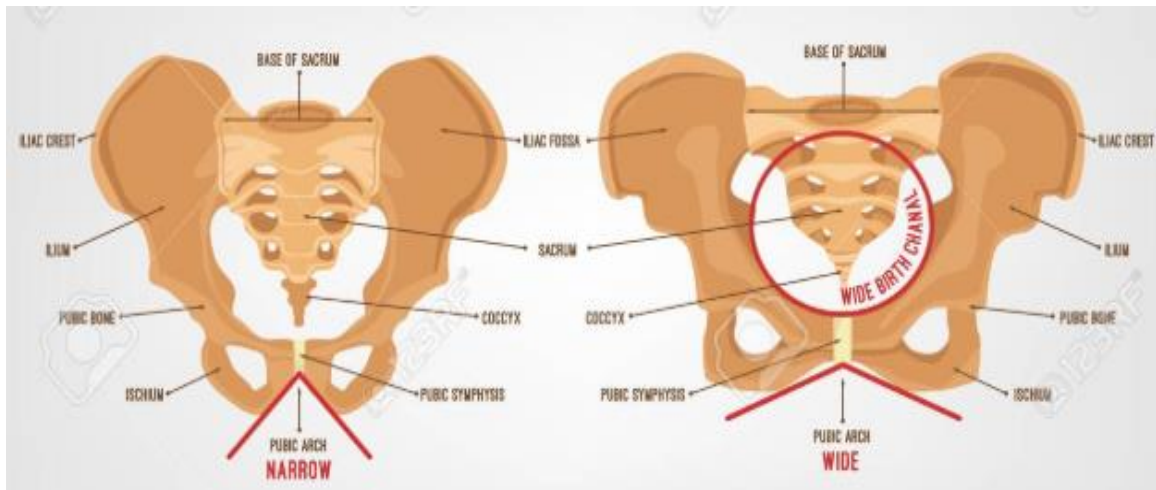


Figure: Sex Difference between Male and Female

Conclusion

In medico-legal cases, the anthropologist face many challenges in which the determination of sex is one of them because only skeleton or some bony parts are found at scene where to determine the sex can narrow down the individuality of person. There are many different ways for sex determination such as

through skull, long bones pelvis. These paper focused on the sex determination through pelvis and concluded that it is a most significant bone to determine the sex difference between male and female as there are many features which vary between males and females.



References:

- Adams, Bradley J. *Forensic Anthropology*. Chelsea House, 2007.
- Burns, Karen Ramey, and Joanna Wallington. *Forensic Anthropology Training Manual*. Routledge, Taylor & Francis Group, 2017.
- Christensen, Angi M., et al. *Forensic Anthropology: Current Methods and Practice*. Academic Press, 2014.
- Dirkmaat, Dennis C. *A Companion to Forensic Anthropology*. Wiley Blackwell, 2015.
- Fairgrieve, Scott I. *Forensic Osteological Analysis: a Book of Case Studies*. Charles C. Thomas, 2010.
- İşcan Mehmet Yaşar, et al. *The Human Skeleton in Forensic Medicine*. Charles C Thomas Publisher, LTD, 2013.
- Klepinger, Linda L. *Fundamentals of Forensic Anthropology*. Wiley-Liss, 2006.
- Márquez-Grant Nicholas, and Julie Roberts. *Forensic Ecology Handbook: from Crime Scene to Court*. John Wiley & Sons, 2012.
- Matshes, Evan W. *Human Osteology & Skeletal Radiology: an Atlas and Guide*. CRC Press, 2005.
- Tersigni-Tarrant, Maria Teresa A., and Natalie R. Shirley. *Forensic Anthropology: an Introduction*. CRC Press, 2013.